



Robert A. Levine DDS, FCPP, Diplomate, American Board of Periodontology
 Clinical Professor, Temple University Kornberg School of Dentistry
 Fellow International Team for Implantology
 Pennsylvania Center for Dental Implants & Periodontics
 Philadelphia, PA



Steven Present DMD, Clinical Associate Professor, Temple University Kornberg School of Dentistry
 Fellow International Team for Implantology
 Private Practice, North Wales, PA



Thomas G. Wilson Jr. DDS, Diplomate of the American Board of Periodontology
 Fellow International Team for Implantology
 Private Practice in Periodontics & Dental Implants
 Dallas, Texas

Complications with excess cement & dental implants: Diagnosis, recommendations & treatment of 7 clinical cases.

Abstract:

Crown restorations associated with dental implants can either be screw or cement retained. In order to make implant retained crowns more like conventional fixed prosthodontics, cementation has become a routine protocol. However, over time it has become evident that residual cement can lead to both soft and hard tissue complications not seen around natural teeth. This may be due to the biological differences in the attachment apparatus between natural teeth and dental implants, the type of cements used, or the cementation techniques employed. Seven cases are presented and discussed stressing the need of early recognition.

KEY WORDS

Dental cement; dental implants; peri-implant disease.

Introduction

Fixed partial dentures associated with dental implants can be either screw-retained or cemented. Initial single tooth implant studies described problems of screw-loosening associated with screw-retention which was largely based on an implant design (external hex-top) which was not ideal for single tooth application. (1) Internal implant connections fared better in this regard with a significant reduction in screw-loosening. (2-4) However the demand for prosthetic simplification lead to the more widespread use of cemented restorations.

While more like conventional crown and bridge these restorations have been found to have negative consequences because of retained cement either on the implant or in the surrounding soft tissues (5) which has contributed to peri-implant diseases (6-8). Peri-implant disease may affect the peri-implant mucosa only (peri-implant mucositis)

or also involve the supporting bone (peri-implantitis) (9-11). Peri-mucositis by recent definition is the presence of inflammation (bleeding upon probing) in the mucosa at an implant with no signs of associated bone loss whereas peri-implantitis is inflammation not restricted to the mucosa and is characterized by loss of bone around the implant. (9, 11) Experimental ligature-induced peri-implantitis and periodontitis were similar to each other histologically however peri-implantitis lesion progressed to a greater extent than the periodontitis lesion. (14) Hence from a clinical point of view, some peri-implant lesions can be expected to progress rapidly and should be treated without delay. (5, 9, 11).

Cementation vs. Screw-retention

The *advantages* of cement retention are:

- less demanding surgical placement
- simpler laboratory techniques
- passive fit
- improved esthetics

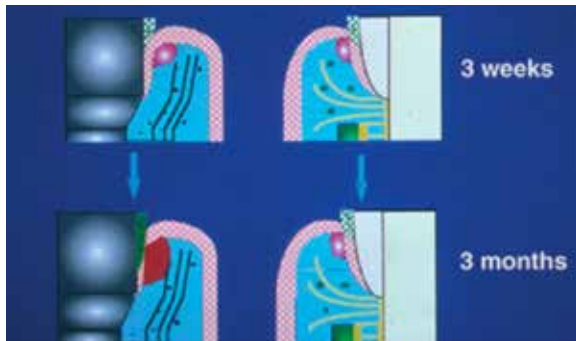

Figure 1 The biology of aggressive periodontitis vs peri-implantitis at three weeks and three months differ significantly. The initial host response at three weeks is identical for the dento-gingival unit and the implant-gingival unit. However, after a biofilm accumulation for three months, the inflammatory infiltrate in the implant-gingival unit was almost three times greater than that of dento-gingival unit. From: Berglundh T, Lindhe J, Marinello C, Ericsson I, Liljenberg B. Soft tissue reaction to de novo plaque formation on implants and teeth. An experimental study in dogs. *Clin Oral Implant Res* 1992; 3: 1-8

- improved control of the occlusion
- elimination of screw-loosening of the screwed retained crown
- lower initial cost of fabrication compared to screw-retention

The *disadvantages* of cement retention;

- inability in some cases to totally remove excess subgingival cement
- lack of predictable retrievability depending upon the type of cement utilize
- depending upon the the design and dimensions of the abutment, resistance and retention can be unpredictable
- possibility of increased maintenance costs due to loss of retention

Anatomical differences between teeth & implants

The structure of the junctional epithelium and perpendicularly inserted connective tissue attachment around natural teeth tends to restrict the flow of excess cement and it becomes compartmentalized and contained. In contradiction, the gingival and connective tissue fibers around dental implants run parallel to the implant body. Therefore, residual cement can migrate apically especially those that are thin and flow easily (such as resin cements). (8,9) The biology of aggressive periodontitis vs peri-implantitis at three weeks and three months differ significantly. The initial host response at three weeks is identical for the dento-gingival unit and the implant-gingival unit. (12) However, after a biofilm accumulation for three months, the inflammatory infiltrate in the implant-gingival unit was almost three times greater than that of dento-gingival unit. (12) See Figure 1. (10)

Excess subgingival dental cement was associated with signs of peri-implant disease in a vast majority (81%) of the cemented cases in a recent study. (5) Clinical and endoscopic signs of peri-implant disease were absent in 74% of the test implants after the removal of excess cement; three cases did require flap surgery for complete cement removal in this study. (5) Of additional concern was that signs of peri-implant disease did not appear in some cases for 91/2 years following cementation.

It is not only necessary for us to devise and employ techniques that will eliminate residual cement, but we must be able to recognize and diagnosis the problem and act aggressively and promptly when a problem does occur. (5-7, 10)

A compounding factor are the cements themselves. Two of the cements used frequently today are specifically designed for implant restorations and are of a particular concern. They are resin based, very thin in consistency and difficult to remove. Wadhvani & Pineryo (8) compared the radiographic density of implant restorative cements and found that some cements commonly used for the cementation of implant supported prosthesis have poor radiodensity and may not be detectable following radiographic examination. Improv Provisional Cement® (Alvelogro, Snoqualime,WA) could only be detectable in thicknesses of 2mm. or greater, Premier Implant Cement® (Premier Dental Products Co, Plymouth Meeting PA) cannot be detected at either 1mm. or 2mm. thick sections. Additionally it has been suggested (Dr. Levine and Dr. Present private conversation with Dr. Wadhvani

regarding a current study at The University of Washington) that these cements actually attract periodontal pathogenic bacteria. In addition, Rely-X Luting Plus (3M ESPE Dental Products, St. Paul, MN) used as an implant cement has similar difficulties.

Diagnosis and treatment of cement-associated peri-implant disease: 7 Cases presented and treated successfully.

Seven diagnosed and treated cases (all surgeries performed by Dr. Levine) are presented with all being healthy, non-smoking women with ages ranging from 40 to 70 years. There were 3 types of cements involved in this 7 case series: 4 were cemented with Premier Implant Cement (cases #1, 2, 5, 7); 2 with Rely-X Luting Plus (cases 3, 4); and 1 with Temp-Bond (Kerr, Orange,CA) (case 6). Rapid and significant bone loss (peri-implantitis) was observed with one of the 2 Rely-X Luting Plus cases (case 4) which was lost to periodontal maintenance for 11 months while the other was diagnosed within 6 months of cementation as peri-mucositis. Peri-implantitis was noted with 2 of the 4 Premier Implant Cement cases (case 2, 7). It is interesting to note that case 2 was under excellent and compliant alternating 3 month periodontal maintenance care which may have limited the amount of bone loss observed. The 2 cases with only peri-mucositis observed with this cement were diagnosed early (6 weeks and 6 months post-cementation) and treated aggressively with exploratory surgery. The longest case treated with peri-implant disease in this case series was cemented with a temporary eugenol-based cement, Temp Bond. Diagnosis of peri-mucositis was

at 1 year post-cementation. This case never progressed to peri-implantitis even though she was unsuccessfully treated for 7 years before performing exploratory surgery. Is the lack of progression into a peri-implantitis

lesion (with bone loss) a nature of the cement having less of a bacterial toxic effect than the other cements associated with peri-implantitis or is it a factor of the patient's periodontal resistance or the proximity of

the cement to the osseous crest? Six of the seven cases only resolved after exploratory surgery with 2 cases also having guided bone regeneration (GBR) to help in bone healing (case 4, 7). (see Table 1)

Case #1

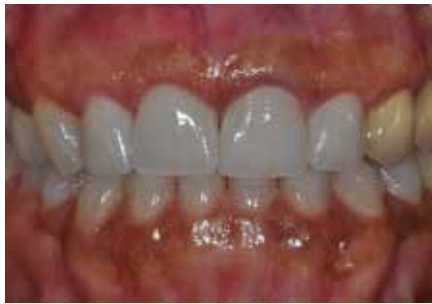

Figure 2a Recently completed single unit fixed partial denture (FPD) with implant in the maxillary right central incisor site replacing a 3-unit FPD in a non-smoking, healthy 58-year old female. Peri-mucositis was noted within 6 months of cementation (surgery: Dr. Robert Levine; Philadelphia, PA).

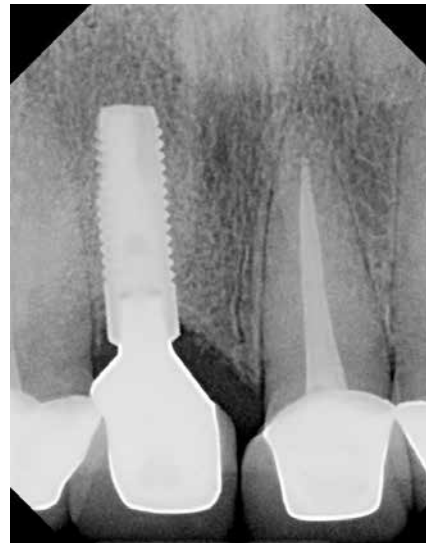

Figure 2b Periapical radiograph shows no signs of subgingival cement.

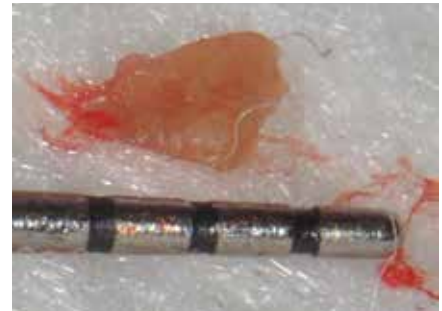
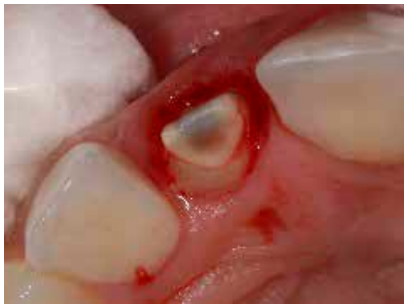
Figure 2c Cement fragment removed nonsurgically.



Figures 2d, 2e Peri-implant mucositis did not resolve and the crown was removed by the restorative dentist to reveal a thin, thumb-nail-thickness of cement still in place on the mesial palatal and mid-palatal and wrapping around to the distal aspects subgingivally.

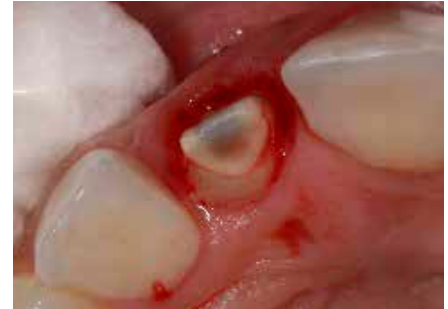
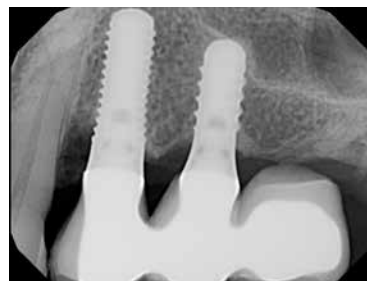
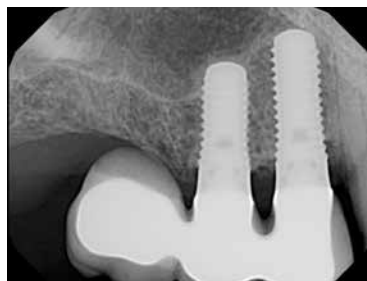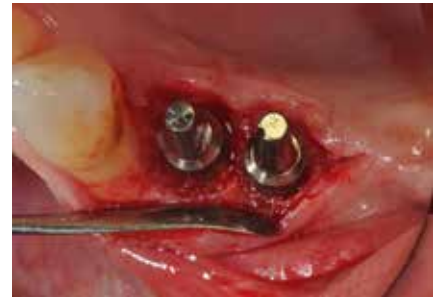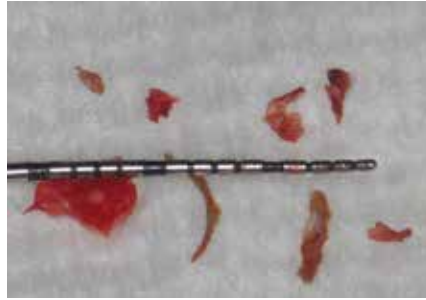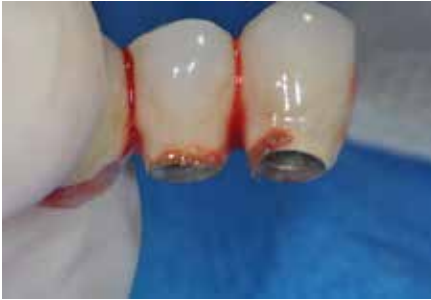Figure 2f Clinical picture 9 months after cement removal. Signs of peri-implant mucositis have resolved.

Case #2



Figures 3a, 3b A non-smoking, healthy 70-year old female presented with a bilateral 3-unit FPD implant-supported restorations placed (3x-4-5; 12-13-14x) two years prior. Peri-implant mucositis developed soon after cementation leading to peri-implantitis around all 4 implant abutments. The patient was very compliant in her maintenance frequency of every 3 months between her periodontist and restorative dentist. Subgingival cement was not seen radiographically however early bone loss was noted associated with all 4 implants. (surgery: Dr. Robert Levine, Philadelphia, PA).

Cement: Premier Implant Cement.



Figures 3c, 3d Recently completed single unit fixed partial denture (FPD) with implant in the maxillary right central incisor site replacing a 3-unit FPD in a non-smoking, healthy 58-year old female. Peri-mucositis was noted within 6 months of cementation. (surgery: Dr. Robert Levine; Philadelphia, PA)

Figure 3e After cement removal from the abutments circumferential bone loss noted around both maxillary right pre-molar implants.

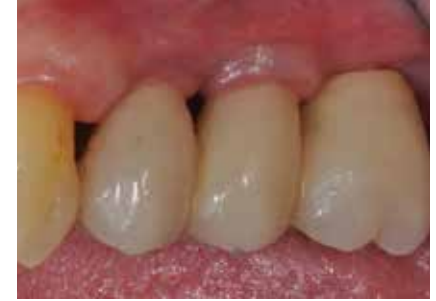
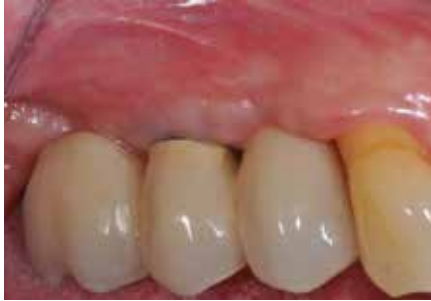
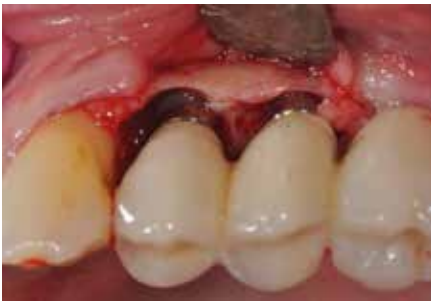Figure 3f Circumferential bone loss noted around both maxillary left premolar implants. After thorough removal of all cement, use of air polisher and surface decontamination with liquid tetracycline for 2 minutes then thorough rinsing with sterile water the flaps were apically positioned and sutured.

Figure 3g, 3h Healing noted 9.5 months after exploratory surgery & cement removal. All clinical signs or peri-implantitis have resolved.

Case #3

A non-smoking, healthy 45-year old female presented with a recently completed implant supported FPD with implants in the position of the mandibular lateral incisors (#23x-24-

25x-26-27x). The periodontal tissues appeared healthy with no clinical signs of peri-implant disease. The final radiographs showed no signs of residual cement. (4/5/11) (surgery: Dr. Robert Levine; Philadelphia, PA.)

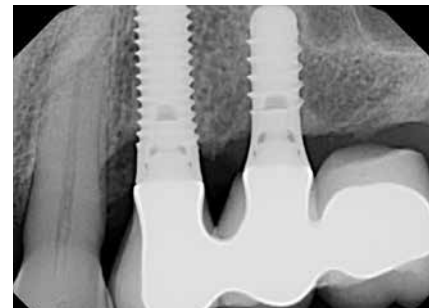
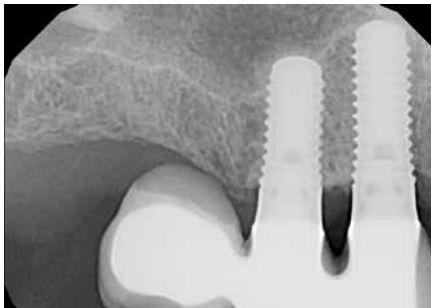


Figure 3i, 3j Radiographic signs of osseous healing noted at 9.5 months post-surgery.

Cement: Rely-X Luting Plus

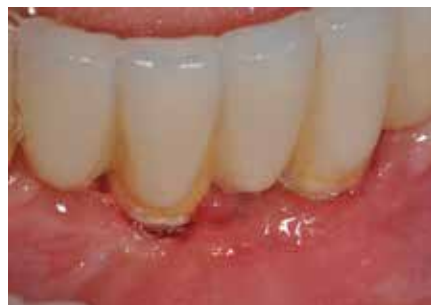
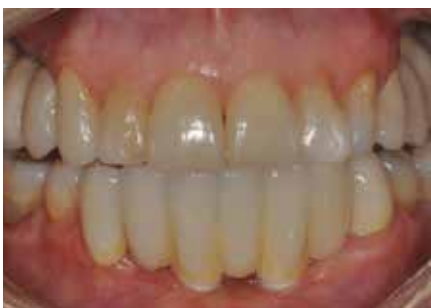
Figure 4a (right) Presentation of case 4 weeks after completion & final cementation.

Figure 4b (left) The patient presented 6 months later at an alternating periodontal maintenance visit with signs of peri-mucositis around abutment implants. (10/17/11). Hard deposits were noted supragingivally as gingival recession has occurred. The consistency was that of a hard resin-cement material.

Case #4

A 55-year old non-smoking, healthy female patient presented with single implant crowns completed recently to replace the maxillary left second premolar and first molar. (5/26/09).

Periodontal tissues were clinically healthy. No radiographic signs of subgingival cement were noted. (surgery: Dr. Robert Levine; Philadelphia, PA.)

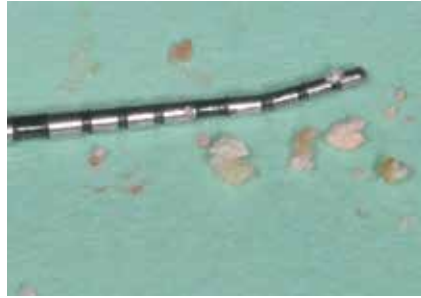

Figure 4c Multiple small and large pieces of cement were removed after exploratory surgery. These pieces were very difficult to remove due to their adaptation to the porcelain/zirconium abutment complex. The implants were thoroughly scaled with titanium hand-instruments and polished with an air polisher. The flaps were then closed.

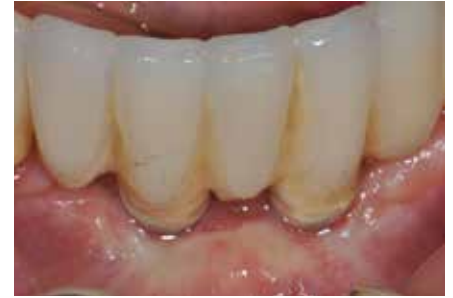

Figure 4d Clinical picture at 5-weeks post-exploratory surgery. Clinical signs of peri-mucositis have been eliminated.

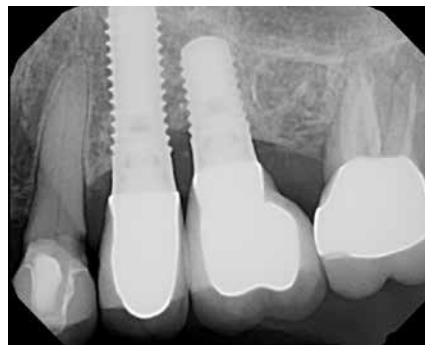
Cement: Rely-X Luting Plus

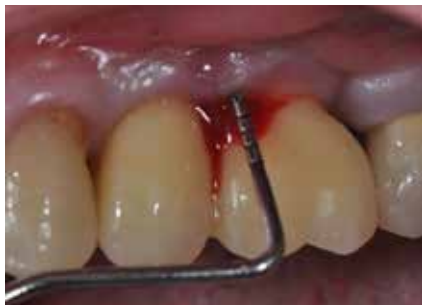
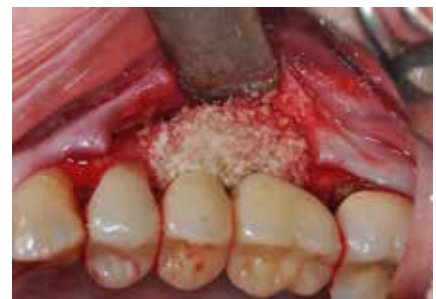
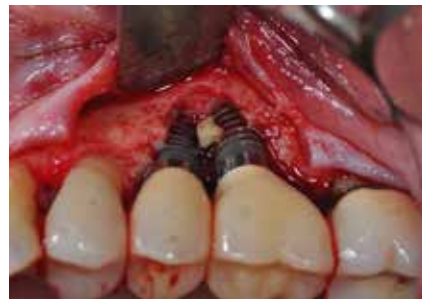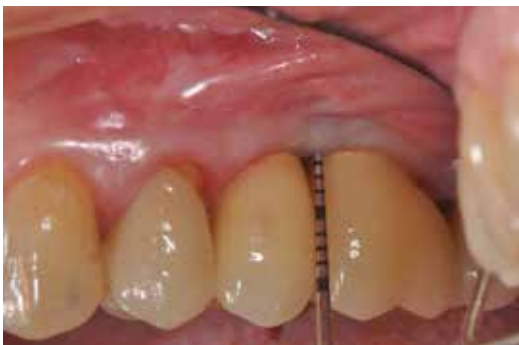Figure 5a The patient presented on emergency 11 months later (5/26/09) from her restorative dentist with suppuration and tenderness around both implants with rapid bone loss and probing depths up to 9 mm on the buccal aspect of the first molar implant. (surgery: Dr. Robert Levine, Philadelphia, PA).



Figures 5b, 5c Full-thickness flaps were raised the areas thoroughly debrided, scaled with titanium curettes, followed by detoxification of the implant surfaces with liquid tetracycline and thorough sterile water rinses. This was followed with the packing of BioOss® soaked in Gem-21® and covered with a BioGide® membrane soaked in Gem-21 then sutured with d-PTFE sutures. The implants were thoroughly scaled with titanium hand-instruments and polished with an air polisher. The flaps were then closed.



Figures 5d, 5e Clinical & radiographic signs of peri-implantitis are absent 2 years later.

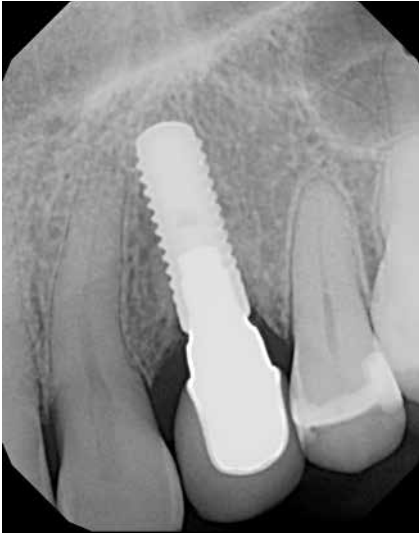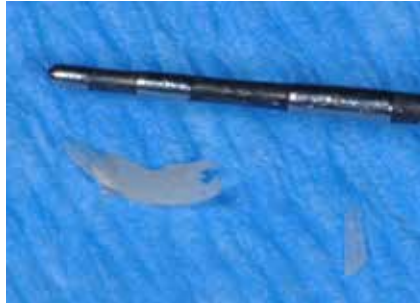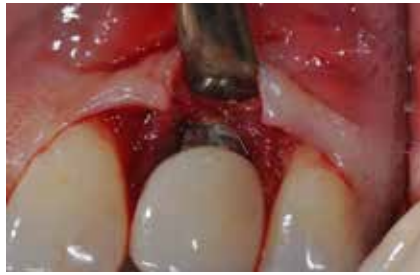Case #5

Figure 6a Clinical appearance of recently restored (approximately 6 weeks) of an immediately placed implant in the maxillary left canine site in a non-smoking, healthy 40-year old female. Clinical signs of peri-mucositis were present and treated non-surgically. There were no signs of radiographic cement or bone loss. (surgery: Dr. Robert Levine, Philadelphia, PA).

Cement: Premier Implant Cement.

Figures 6b & 6c Exploratory surgery revealed an adherent piece of cement mid-buccal adhered to the abutment from the crown margin to the osseous crest. The cement pieces were of fingernail thickness.

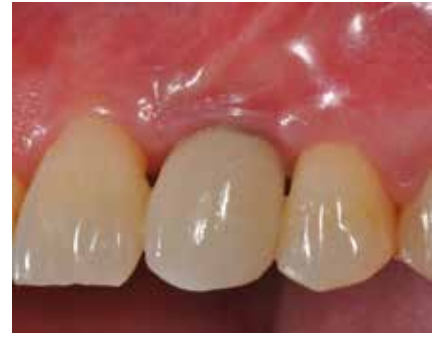

Figure 6d 9-week post-exploratory surgery shows clinical signs of peri-mucositis have resolved.

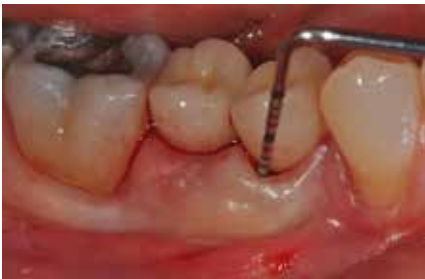Case #6

Figure 7a A 54-year old non-smoking, healthy female presented with splinted implants in the mandibular right first molar which were placed over 8 years prior. Signs of peri-mucositis started approximately 1 year later and was treated with non-surgical therapy & subgingival antibiotic placement and systemic doxycycline 20mg therapy which did not totally resolve her peri-mucositis with 5-6 mm probing depths. There was no radiographic bone loss noted. (surgery: Dr. Robert Levine, Philadelphia, PA).

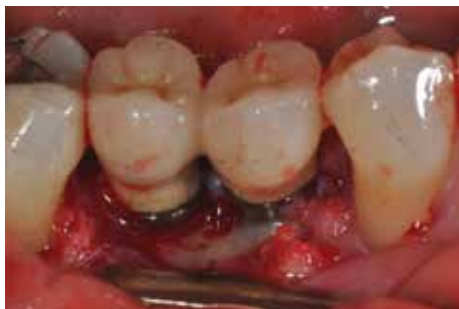Cement: Premier Implant Cement.

Figure 7b Exploratory surgery completed with cement removed with titanium implant curettes, the implant surfaces detoxified with tetracycline liquid for 2 mins. Followed by air polisher with thorough sterile water rinses then sutured. No clinical bone loss was noted.

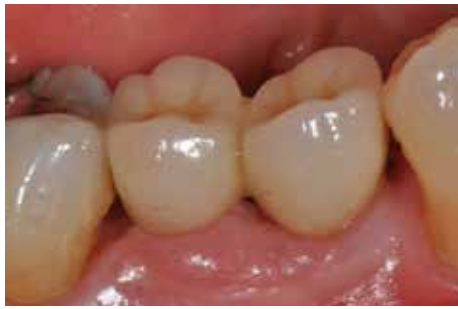
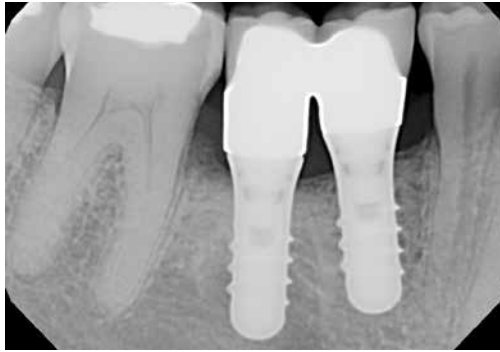
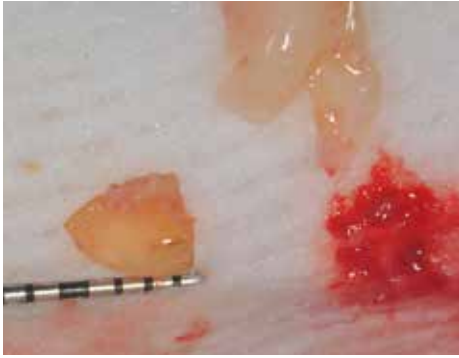Figure 7c Cement pieces removed.



Figures 7d & 7e Clinical & radiographic appearances 5 months post-exploratory surgery. Clinical signs of peri-mucositis have been eliminated (2-21-12).

Case #7

Cement: Premier Implant Cement

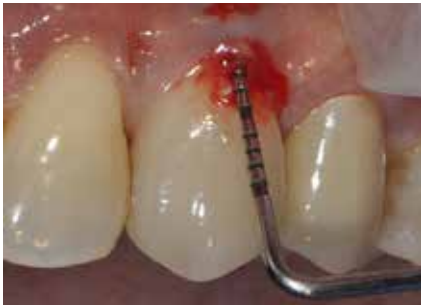

Figure 8a A 58-year old non-smoking, healthy female presented after maxillary left canine implant crown was completed 1.5 years prior with clinical signs of peri-implantitis. (Surgery: Dr. Robert Levine, Philadelphia, PA.)

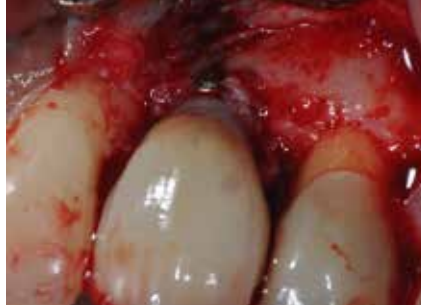

Figure 8b Exploratory surgery revealed a very thin painted-on appearance of the resin cement on the titanium abutment just under the crown margin which was difficult to remove.

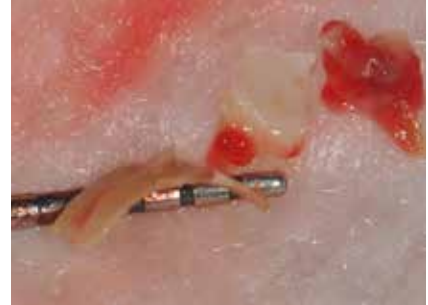

Figure 8c Pieces of the cement which were removed. Note the piece on the periodontal probe gives the appearance of a thin fingernail.

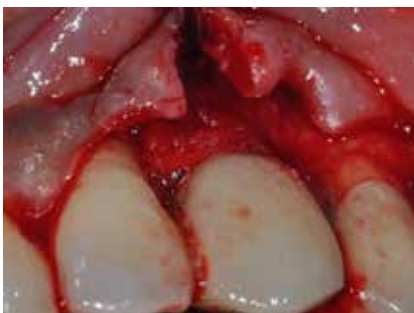

Figure 8d The implant was thoroughly scaled with titanium curettes, cleaned, and detoxified with EDTA PreFgel® Institut Straumann AG, Basel Switzerland for 2 minutes. (Enamel matrix derivative - Emdogain® Institut Straumann AG, Basel Switzerland) was then applied and covered with a thick collagen membrane (MucoGraft®; Geistlich, Wolhusen, Switzerland) for GBR and to help restore buccal contours which had been partially lost due to buccal bone loss of 2-3mm.

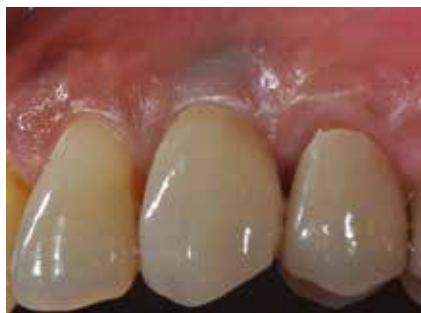

Figure 8e Clinical health has been reestablished at 7.5 months post-exploratory surgery & GBR (12/7/11).

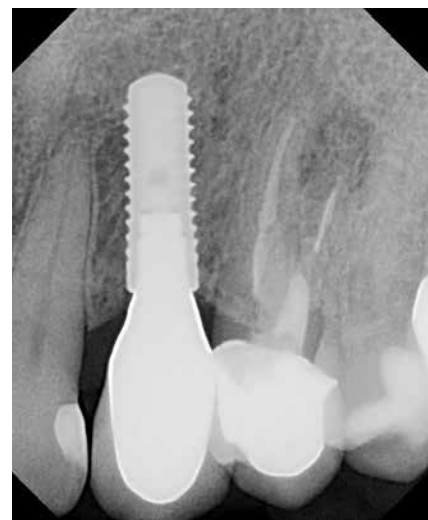

Figure 8f No radiographic bone loss was noted.

Case	Cement	Diagnosis	Time to Clinical Presentation	Treatment	Outcome
1	Premier Implant Cement*	Peri-mucositis	6 Months	Non-surgical Crown removal	Resolved
2	Premier Implant Cement*	Peri-implantitis	24 Months	Surgical, detoxification with out graft or membrane	Resolved
3	RelyX Luting Plus**	Peri-implantitis	6 Months	Surgical, detoxification with out graft or membrane	Resolved
4	RelyX Luting Plus**	Peri-implantitis	11 Months	Surgical, detoxification BioOss, Gem21 Membrane	Resolved
5	Premier Implant Cement*	Peri-implantitis	6 Weeks	Surgical, detoxification with out graft or membrane	Resolved
6	Temp-Bond***	Peri-mucositis	12 Months - 48 Months	@12 months non-surgical with antibiotics @ 48 months surgical detoxification with out graft or membrane	Unresolved Resolved
7	Premier Implant Cement*	Peri-implantitis	20 Months	Surgical, detoxification EDTA, Emdogain, membrane	Resolved

* Resin cement
 ** Resin modified glass ionomer cement
 *** Zinc oxide eugenol cement

Table 1: Case Summary Discussion

Clinical goals when treatment planning dental implants include long-term solutions with minimal long-term problems for all patients. The clinical problems we are now seeing more frequently with especially resin-based cements used for implant cementation cannot be understated. The first author is seeing on average 1-3 new cases per month of peri-mucositis and/or peri-implantitis associated with cement-retained implant restorations. The time-frame of initial signs of peri-implant disease post-cementation is as short as 6 weeks (case #5) to 4 months and as long as 9 years. (5) Close clinical monitoring of all implant cases by the dental team has become a necessity. Documented periodontal probing of implant cases to determine signs of early peri-implant disease (peri-mucositis-bleeding upon light probing involving only soft tissue involvement) to later signs (peri-implantitis with accompanying radiographic bone loss) is necessary as with all periodontal patients. It is recommended to identify which cement was used as well as any subsequent re-cementation and to treat it aggressively when a poor response to non-surgical periodontal therapy is noted. There now is evidence in the literature which supports the need for an exploratory surgical or endoscopic procedure to be sure of complete cement removal as demonstrated by failure non-surgically in this report and observations by

others (5-7,10). The various surgical treatments which were employed in our cases were based on the extent of peri-implant disease at presentation. Implant detoxification was completed for all surgical cases after the complete removal of cement and granulomatous tissue. This was followed by apical repositioning of the flaps as in cases #2 and #6 or repositioning of the flaps as in case #5 for pocket reduction. In a more severe case of peri-implantitis as in case #4 mineralized freeze-dried bone allograft was soaked in a biologic growth factor (PDGF-Gem 21@ Osteohealth; Shirley,NY) and was used for bone regeneration and gingival flap support. A collagen membrane was used to protect the graft and act as a barrier for guided bone regeneration. The various protocols employed were based upon successful surgical principals of guided tissue regeneration and periodontal pocket reduction therapy techniques used to treat periodontal disease. A recent study has reported on a standardized protocol for the successful treatment of peri-implantitis which employs similar rationales and materials as in our cases. Froum et al reported on 51 consecutively treated cases with follow-ups between 3-7.5 years. Their protocol included surface decontamination, use of enamel matrix derivative, a combination of PDGF with anorganic-bovine bone or mineralized freeze-dried bone, and coverage with a collagen membrane or a subepithelial connective tissue graft (used with a lack of keratinized gingiva on the buccal aspect pre-surgery). Bone level gain at follow-up ranged between 3-3.75mm based on the treatment group (13)

Cements can act as subgingival reservoirs for bacteria and their by-products similar to subgingival calculus. They adhere extremely well to titanium and porcelain surfaces. If non-surgical therapy is attempted to treat a tentative diagnosis of excess subgingival cement then reevaluation of the soft tissues in 4-6 weeks is recommended. Clinicians are guided only by clinical signs of peri-mucositis early on with especially resin-based cements since they are not observable radiographically. (7) Determination then needs to be made for conservative exploratory surgery based on clinical indices of continued increased probing depth (greater than or equal to 6mm) and/or persistent bleeding upon probing. (5,10) The reference point for subgingival margins in the past has been 1-2mm. (14) For esthetic reasons it has been recommended greater than 2 mm subgingival placement of crown margins for improved crown emergence profile. (14) Linkevicius et al. (9) tested experimentally casted prosthetic abutments with 5 different locations of cement margins using resin-modified glass-ionomer cement (Fuji Plus (GC, Tokyo, Japan) and found it was impossible to clean excess cement around the implant restorations with subgingival margins, especially those positioned 2mm or deeper. Those margins which were 1mm supragingival or at the level of the gingival margin had almost all cement removed. (9) They concluded that the deeper the restorative margin was located the more cement remnants were remained overlooked. (9) These results confirm Agar et al who reported that 1.5mm-3mm subgingivally placed margins were also difficult for cement removal as well. Agar et al also noted extensive scratching occurs on the abutments in the attempts of cement removal which can become plaque retentive areas. (15) The present study confirms these results as all margins were placed within 2mm-3mm of the gingival margins with either custom or standard abutments using the team approach of the periodontist helping in the determination of abutments to be used based on tissue depths at the final post-op visit prior to commencing prosthetic treatment.

These visits were most often coordinated immediately with the restorative office the same day. The properties of these luting cements with a resin component is the most difficult to remove from polished abutment surfaces. (9,15) Linkevicius et al. recommends

that clinicians should select cements with less adhesive properties for cementation of implant restorations. (9) Clinicians are also prone to significantly overestimate their ability to remove all cement post-cementation both in vitro as well as in a clinical study. (5,9) If one still desires to use a cemented restoration then the following would be recommended: keep margins no deeper than 1 to 1.5mm and if possible bring the margin to the gingival margin or slightly supra-gingival to be visible. Since the depth of the abutment was more important than its shape of the abutment (following the contours of the CEJ) keeping the margins at or close to the gingival margin is the key as the greatest amount of cement remnants are when crown margins were placed at 2-3mm below the gingival level. (9) This can be achieved in non-esthetic areas and even in high esthetic areas when using zirconium abutments. A careful cementation technique is always recommended using a less adhesive cement using a technique such as the rubber dam technique presented or Wadhvani & Pineryo's(8) described method using Teflon (plumber's) tape which was also described. With either technique, there should be little to no excess cement. In addition, a bacteriostatic cement is also recommended (ie. zinc

phosphate) with the avoidance of resin-based cements. Avoiding cement altogether and using a screw-retained (occlusal or lingual set-screw) would be appropriate as well. Most importantly continuous team work between the restorative and surgical offices is advised from case planning to final prosthesis for both cemented and screw-retained restorations and its periodontal follow-up and early treatment when a problem is diagnosed. (5)

Conclusions

There have been a number of documented cases in the dental literature with peri-implant disease associated with residual subgingival dental implant cement. Based on these studies and the 7 cases presented the proper recommended location of the cemented implant crown margin needs to be re-addressed. Today, the ideal recommendation is that the margin should be clinically visible or no more than 1.5mm subgingival as complete cement removal is impossible over 2mm in depth. The alternative approaches of occlusal or lingual set-screw retention should also be viewed as an appropriate choice. If cementation is to be used, careful and thorough attempts at cement removal is necessary with the

avoidance if possible of resin-based cements due to their physical properties of extreme thinness and flowability upon setting and the inability to be detected radiographically as well as clinically. If residual cement is suspected and its non-surgical treatment has not been successful in removing signs of peri-implant disease then a conservative exploratory procedure is necessary with evaluation for diagnosis confirmation and thorough removal of all cement remnants on the implant crown and abutment surface as well as in the tissues. The adjacent tissues need to be addressed as the cement fragments can be displaced after being pulverized into smaller pieces during instrumenting non-surgically. If bone loss is noted the clinician may decide on a regenerative course of action at the time of exploratory surgery using the principles of guided bone regeneration (GBR).(13) Close periodontal monitoring of all implant cases is important and early treatment of peri-implant disease is recommended as studies have shown potentially more rapid bone can be observed associated with peri-implant disease than its counterpart of periodontitis due to the histological differences of their soft tissue attachment apparatus.

References

- Avivi-Arber L, Zarb GA. Clinical effectiveness of implant-supported single-tooth replacement: The Toronto study. *Int J Oral Maxillofac Implants* 1996; 11: 311-321.
- Levine RA, Clem DS III, Wilson TG Jr, Higginbottom F, Solnit G. Multicenter retrospective analysis of the ITI implant system used for single-tooth replacements. Results of loading for 2 or more years. *Int J Oral Maxillofac Implants* 1999; 14: 516–520.
- Levine RA, Ganeles J, Jaffin RA, Clem DS III, Beagle JR, Keller JW. Multicenter Retrospective analysis of wide-neck dental implants for single molar replacement. *Int J Oral Maxillofac Implants* 2007; 22: 736-742.
- Jung RE, Pjetursson BE, Glauser R, Zembic A, Zwahlen M, & Lang NP. A systematic review of the 5-year survival and complication rates of implant-supported single crowns. *Clinical Oral Impl Res* 2008; 19: 119-130
- Wilson TG Jr, The positive relationship between excess cement and peri-implant disease: a prospective clinical endoscopic study. *J Periodontol* 2009; 80: 1388-1392.
- Pauletto NP, Lahiffe BJ, Newton JN. Complications associated with excess cement around crowns on osseointegrated implants: a clinical report. *Int J Oral Maxillofac Implants* 1999; 14: 865-868.
- Gapski R, Neugeboren N, Pomeranz AZ, Reissner MW. Endosseous implant failure influenced by crown cementation: a clinical case report. *Int J Oral Maxillofac Implants* 2008; 23: 943-946.
- Wadhvani Ch. & Pineryo A. Technique for controlling the cement for an implant crown. *J of Prosth Dent* 2009; 107: 57-58.
- Linkevicius T, Vindasiute E, Puisys A, Peciuliene V. The influence of margin location on the amount of undetected cement excess after delivery of cement-retained implant restorations. *Clin Oral Impl Res* 2011; 22: 1379-1384.
- Heitz-Mayfield LJA, Lang NP. Comparative biology of chronic & aggressive periodontitis vs. peri-implantitis. *Periodontology* 2000 2010; 53: 167-181.
- Zitzmann NY, Berglundh T. Definition and prevalence of peri-implant diseases. *J Clin Periodontol* 2008; 35: 286-291.
- Berglundh T, Lindhe J, Marinello C, Ericsson I, Liljenberg B. Soft tissue reaction to de novo plaque formation on implants and teeth. An experimental study in dogs. *Clin Oral Implant Res* 1992; 3: 1-8
- Froum SJ, Froum SH, Rosen PS. Successful management of Peri-implantitis with a regenerative approach: Implants with 3-to-7.5-year follow-up. *Int J Periodontics Restorative Dent* 2012; 32: 11-20.
- Belser UC, Buser D, Hess D, Schmid B, Bernard JP & Lang NP. Aesthetic implant restorations in partially edentulous patients-a critical appraisal. *Periodontol* 2000 1998; 17: 132-150.
- Agar JR, Cameron SM, Hughbanks JC & Parker MH. Cement removal from restorations luted to titanium abutments with simulated subgingival margins. *J of Prosth Dent* 1997; 78: 43-47.